

# Hamstring Anterior Cruciate Ligament Reconstruction with IntraFix Tibial Fastener

# 47

## CHAPTER

Joseph H. Sklar  
Charles H. Brown, Jr.

### INTRODUCTION

s0010

p0010

[Au1]

The optimal initial graft fixation technique for hamstring tendon anterior cruciate ligament (ACL) grafts remains controversial.<sup>1-10</sup> Biomechanical studies have demonstrated that cross-pin and Endobutton-CL femoral fixation techniques provide excellent initial fixation properties.<sup>11,12</sup> However, tibial fixation of hamstring tendon ACL grafts has been more problematic. This is primarily due to the lower bone mineral density of the proximal tibia and the fact that tibial fixation devices must resist tension applied parallel to the axis of the tibial bone tunnel.<sup>13-16</sup> Extratunnel tibial fixation techniques that anchor to the tibial cortex can provide secure initial fixation; however, the implants are often prominent and cause local skin irritation and pain, requiring a second operation for removal.<sup>17</sup> Intra-tunnel tibial fixation using interference screws eliminates the problem of prominent hardware, but the single interference screw technique has been shown to have somewhat low initial fixation strength and increased slippage under cyclical loading.<sup>13-15,17-19</sup>

p0020

[Au2]

The IntraFix tibial fastener was designed with two goals in mind, one mechanical and one biological. The first goal was to achieve more rigid intratunnel fixation of soft tissue grafts and eliminate or decrease the need for supplemental tibial fixation. The second goal was to maximize bony integration of the soft tissue graft strands into the bone tunnel wall. To achieve these goals,

the device was designed with an expandable, four-channel, ridged, 30-mm polyethylene sheath and a tapered Delrin expansion screw. The four channels individually capture and grip each of the four strands of the hamstring tendon graft into separate compartments and directly compress each of the graft strands against cancellous bone. We performed cyclical and single load to failure (LTF) tests comparing the plastic IntraFix and bioabsorbable interference screws in paired young to middle-aged human cadaver tibiae with human doubled gracilis and semitendinosus grafts (DGSTs) (Table 47-1). The plastic IntraFix demonstrated a mean ultimate failure load of 800N and stiffness of 200 N/mm, which was significantly higher than interference screw fixation. In an independent biomechanical study comparing commonly used hamstring tendon graft tibial fixation devices, Kousa et al<sup>20</sup> demonstrated that the IntraFix had the highest LTF (1309N) and stiffness (267 N/mm) and the least amount of slippage (1.5 mm) after cyclical loading.

Following the successful clinical introduction of the nonabsorbable IntraFix tibial fastener, a Bio-IntraFix composed of PLLA/TCP was developed to satisfy the desire of some surgeons for a bioabsorbable device. Testing of the Bio-IntraFix using DGST and paired human cadaveric tibiae (mean age  $63 \pm 10$  years) was performed with the line of force applied parallel to the axis of the tibial tunnel. Elongation was measured using a video camera system to determine displacement of contrast

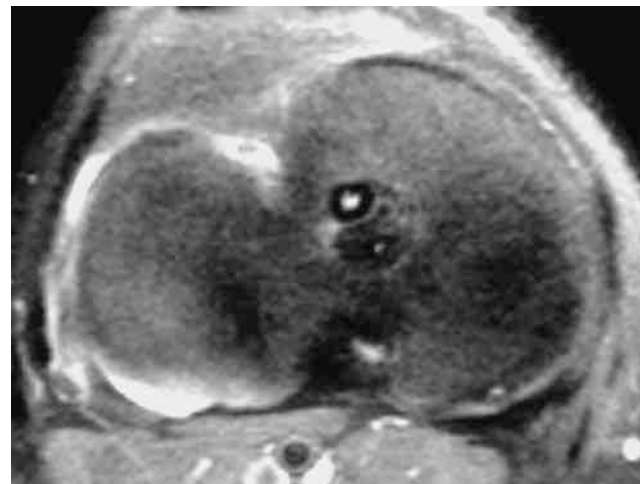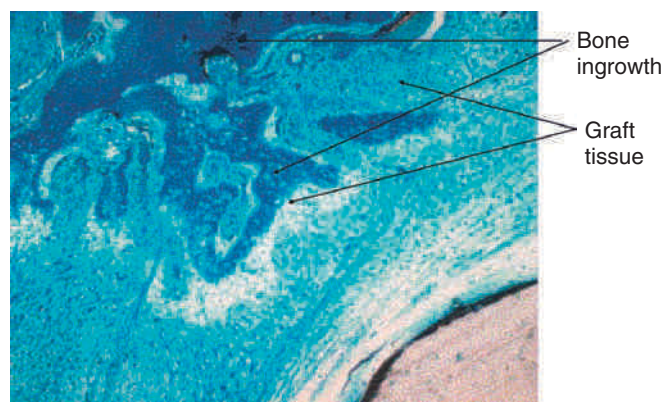
f0010 **TABLE 47-1** Sizing Scheme for Bio-IntraFix

Graft Diameter	Drill Tunnel	Screw Size
7 mm	8.5 mm	6–8 mm
8 mm	9.0 mm	6–8 mm
9 mm	10.0 mm	7–9 mm
10 mm	11.0 mm	8–10 mm

markers attached to the graft and bone. The graft–Bio-IntraFix–bone complex was cyclically loaded between 50N and 200N at a rate of 0.5 Hz for 1000 cycles (33 min, 20 sec). One thousand cycles approximates 1 week of post-operative intermittent passive motion. The mean ultimate failure load and linear stiffness for the Bio-IntraFix were  $643 \pm 152\text{N}$  and  $325 \pm 111\text{ N/mm}$ , respectively. Elongation after 1000 cycles was  $2.28 \pm 1.19\text{ mm}$ . The failure load of the Bio-IntraFix was found to be superior to that of the Delta screw (Arthrex, Naples, FL), and the stiffness was two times that of the Delta Screw. During cyclical loading, three of six Delta screws failed compared with only one of six DGST grafts fixed with the Bio-IntraFix.

p0040

The second goal of this design was to maximize the amount of contact between graft tendons and bone. Fixation outside tunnels and from suspension devices results in a loose fibrous attachment between the tunnel wall and the graft, with little if any bony ingrowth into the graft. In contrast, direct compression of tendon to bone by interference screws within the tunnel leads to bony ingrowth including Sharpey fiber formation.<sup>19</sup> However, a single interference screw inserted next to a bundled four-stranded graft definitely leaves a considerable portion of the tunnel filled by the screw and some of the tendons without bony contact. In contrast, the IntraFix has the potential for more extensive bone–graft integration because each strand is pressed against bone and the entire tunnel wall is in contact with graft. A limited histological study performed on the IntraFix in sheep demonstrated early bony integration (Fig. 47-1). Thus extrapolation of the interference screw data to this device seems justified. Further evidence of extensive bony integration when using the IntraFix and Bio-IntraFix comes from direct examination of the tibial tunnel many months after reconstruction. Fig. 47-2 shows an example of the appearance of the tibial tunnel 1 year after ACL reconstruction; it was obtained during a revision case after the sheath had been removed and the arthroscope inserted into the tibial tunnel. It shows a firm surface, apparent integration of the sutured tendons into the bone tunnel wall, capillary ingrowth, and no loose fibrous tissue.

f0010 **FIG. 47-1** Transaxial magnetic resonance image of the tibia in an anterior cruciate ligament (ACL) reconstructed patient showing a cannulated screw anteriorly and a graft bundle posteriorly. Note the very limited contact of the graft bundles with the surface of the bone tunnel.f0020 **FIG. 47-2** Histology 12 weeks after reconstruction of the anterior cruciate ligament (ACL) in a sheep using autogenous extensor tendons and tibial fixation with IntraFix, seen at the bottom right of slide. Note Sharpey fiber formation (linear strands) and new bone ingrowth (dark blue) into tendon (light blue).

## SURGICAL TECHNIQUE

s0020

### Graft Preparation

s0030

Preparation of the tendons is facilitated by the use of a graft preparation board. The two tendons are cut to a total length of 20 to 21 cm, and the opposite ends of the tendons are whipstitched for 4 to 5 cm using a #2 nonabsorbable suture. This length of tendon graft allows for 25 mm of the DGST tendon graft to be inserted into the femoral tunnel and typically results in a significant length of suture-reinforced tendon within the tibial tunnel and a short (1-cm) length of the tendons extending outside the tibial tunnel. If more of the DGST tendon graft is inserted into the femoral tunnel, or if the tibial tunnel is longer than 40 to 45 mm, then the

p0050

total length of the two tendons should be increased accordingly. This is important because suture-reinforced tendon constructs have been shown to increase pullout strength by 30% to 40% in our laboratory biomechanical tests.

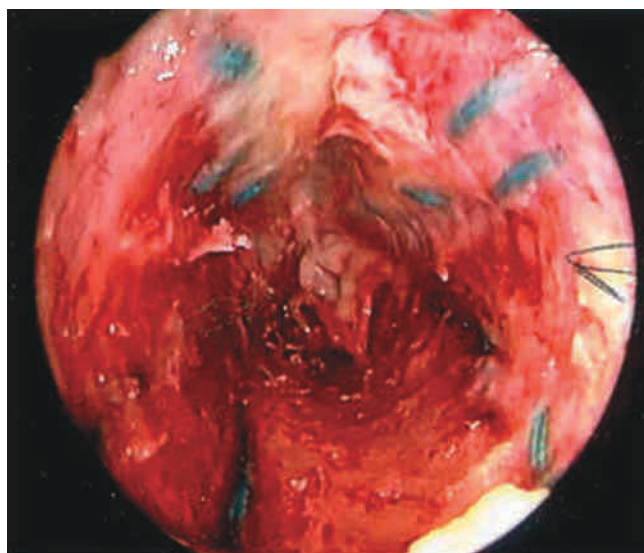
#### s0040 Use with Allografts

p0060 If a soft tissue allograft such as a tibialis tendon is used, we prefer to divide each end of the allograft in two for a distance of 5 cm and then to whipstitch each strand so that a four-stranded construct comparable to a DGST is created. The IntraFix four-chambered sheath accommodates and provides more uniform compression with a four-strand graft preparation compared with a two-stranded graft. The graft construct is then placed on a tensioning board, cinching the whipstitched sutures and removing creep from the graft construct. Removing creep from the graft-suture construct is particularly important if supplemental fixation is required.

#### s0050 Tibial Tunnel

p0070 Our preferred method for performing endoscopic ACL reconstruction is the transtibial tunnel technique (Fig. 47-3).

**Au5** The transtibial technique allows a longer femoral tunnel to be drilled compared with drilling the femoral tunnel through the anteromedial portal and also allows cross-pins to be used for the femoral fixation. Another advantage of the transtibial technique is that the femoral tunnel does not have to be drilled with the knee in hyperflexion, which constricts fluid inflow and limits visualization in the notch. The disadvantage of the transtibial tunnel technique is that it provides more limited access to the sidewall of the lateral femoral condyle compared



f0030 **FIG. 47-3** Appearance of the tibial tunnel using an arthroscope during revision surgery following removal of the IntraFix device. Note the apparent integration of tendons/sutures 360 degrees around the tunnel and imprint of the sheath's ridges.

with drilling the femoral tunnel through the anteromedial portal.

The tibial tunnel must be carefully oriented in both the sagittal and coronal planes for several reasons. Due to the large cross-sectional area of four-strand hamstring tendon grafts, sagittal placement of the tibial tunnel is especially critical.<sup>21</sup> The tibial tunnel position in the sagittal plane determines whether the ACL graft impinges against the roof of the intercondylar notch in full knee extension.<sup>22-24</sup> Roof impingement is associated with effusions, loss of extension, anterior knee pain, quadriceps weakness, and increased anterior laxity.<sup>24</sup> Coronal plane orientation is the primary determinant of placement of the femoral tunnel along the side wall of the intercondylar notch and, to some degree, of the length of the femoral tunnel. A more medial starting position on the tibia allows the femoral tunnel to be drilled closer to the 10- or 2-o'clock position along the sidewall. A femoral tunnel at the 10-o'clock (right knee) or 2-o'clock position (left knee) is important because a single-bundle ACL graft positioned at these locations in the intercondylar notch is more effective at resisting combined rotatory loads than one placed at the 11-o'clock position. Biomechanical studies have demonstrated little difference in coupled anterior tibial translation between this graft and a double-bundle hamstring ACL reconstruction at low degrees of flexion.<sup>17,25</sup>

In our surgical technique, a tibial tunnel length of 35 to 45 mm is optimal because this will accommodate the entire 30-mm IntraFix or Bio-IntraFix with no chance of the device protruding into the joint. In general, setting the variable angle tibial aimer between 45 and 55 degrees will allow these tibial tunnel lengths to be achieved. The guidelines of Jackson and Gasser,<sup>26</sup> Howell,<sup>19</sup> and Simmons et al<sup>27</sup> are used for intraarticular placement of the tibial guide pin. If necessary, the tibial guide pin position can be checked by intraoperative radiographs or fluoroscopy with the knee in maximum extension.

#### Tunnel Sizing

When using the plastic IntraFix, the diameter of the tibial tunnel should equal the diameter of the suture-reinforced end of the graft. When using the Bio-IntraFix, the tibial tunnel should be drilled 0.5 to 1.0 mm larger than the diameter of the suture-reinforced end of the graft because the Bio-IntraFix sheath does not compress or flow during screw insertion. Biomechanical testing of this oversized scheme showed no loss of fixation strength for the Bio-IntraFix compared with tunnels sized to the same diameter as the graft. Half-millimeter-sized drill bits can be used to make this sizing more precise. The tibial tunnel should be drilled with a fluted drill to prevent anterior drift of the tunnel as the proximal cortex is breeched.

After drilling the tibial tunnel, it is important to clear soft tissue from around the edges of the tibial tunnel using

p0090

s0060

p0100

p0110



an electrocautery pencil and a Cobb periosteal elevator for several reasons. First, a clear view is necessary to ensure that the tab of the IntraFix sheath is flush with the tibial cortex and that the sheath is fully inserted. Second, a clear view helps ensure that the screw is neither over- nor under-inserted into the tunnel. Finally, clearing of soft tissue also improves the ability to see and trim excess tendon and sheath at the end of the case so that there is no prominence that might later irritate the patient.

s0070

### Femoral Tunnel and Graft Fixation

p0120

Because the IntraFix tibial fastener can be used with any femoral fixation technique, the choice of the femoral fixation is based on the surgeon's preference. However, we prefer cross-pins or the Endobutton-CL because these fixation techniques have been shown to be strong and stiff and to have the least amount of elongation under cyclical loading.<sup>11,12</sup> More importantly, these two femoral fixation techniques permit equal tensioning of all four graft strands. This is an important goal because, as shown by Hamner et al,<sup>23</sup> it is necessary to equally tension all four strands of a DGST graft to maximize initial graft strength and stiffness. An *equally tensioned* DGST graft was stronger and stiffer than a 10-mm, central-third patellar tendon autograft. However, when no attempt was made to equally tension all four graft strands, the ultimate failure load and stiffness of the DGST graft were not statistically different from that of a doubled semitendinosus tendon graft alone. Thus failure to equally tension all four graft strands of a DGST graft negated any contribution from the doubled gracilis tendon graft.

s0080  
Au6  
p0130

### Graft Passage, Graft Tensioning, and Tibial Fixation

For the IntraFix device to function properly, the strands of the graft need to be parallel and untangled within the tibial tunnel. This can be accomplished easily if the surgeon arranges the strands in this way as the graft is drawn into the knee by the assistant.

p0140

After the femoral side of the DGST or tibialis tendon allograft has been securely fixed in the lateral femoral condyle, the whipstitches from the gracilis tendon or corresponding opposite ends of the tibialis tendon allograft are tied together to create a loop approximately 4.5 to 5 inches from the end of the tibial tunnel. This step is repeated for the semitendinosus tendon and the corresponding opposite ends of the tibialis tendon allograft (Fig. 47-4, *A* and *B*).

p0150

The two suture loops are placed around the tie tensioner (DePuy Mitek, Norwood, MA) but can be held by hand. The tie tensioner frees one hand for the surgeon. Because it contains a calibrated spring, it allows for quantification of the tension applied to the graft at the time of fixation. Prior

to inserting the IntraFix, the knee is cycled from 0 to 90 degrees approximately 25 to 30 times with a tension of 60N to 80N maintained on the graft limbs. The tie tensioner will equally tension and separate each strand of the DGST graft. Cycling allows stress relaxation of the femoral fixation device, allows the tendons to compress around the cross-pin or Endobutton-CL, and removes creep from the DGST or tibialis tendon allograft and the tendon whipstitches.

p0160

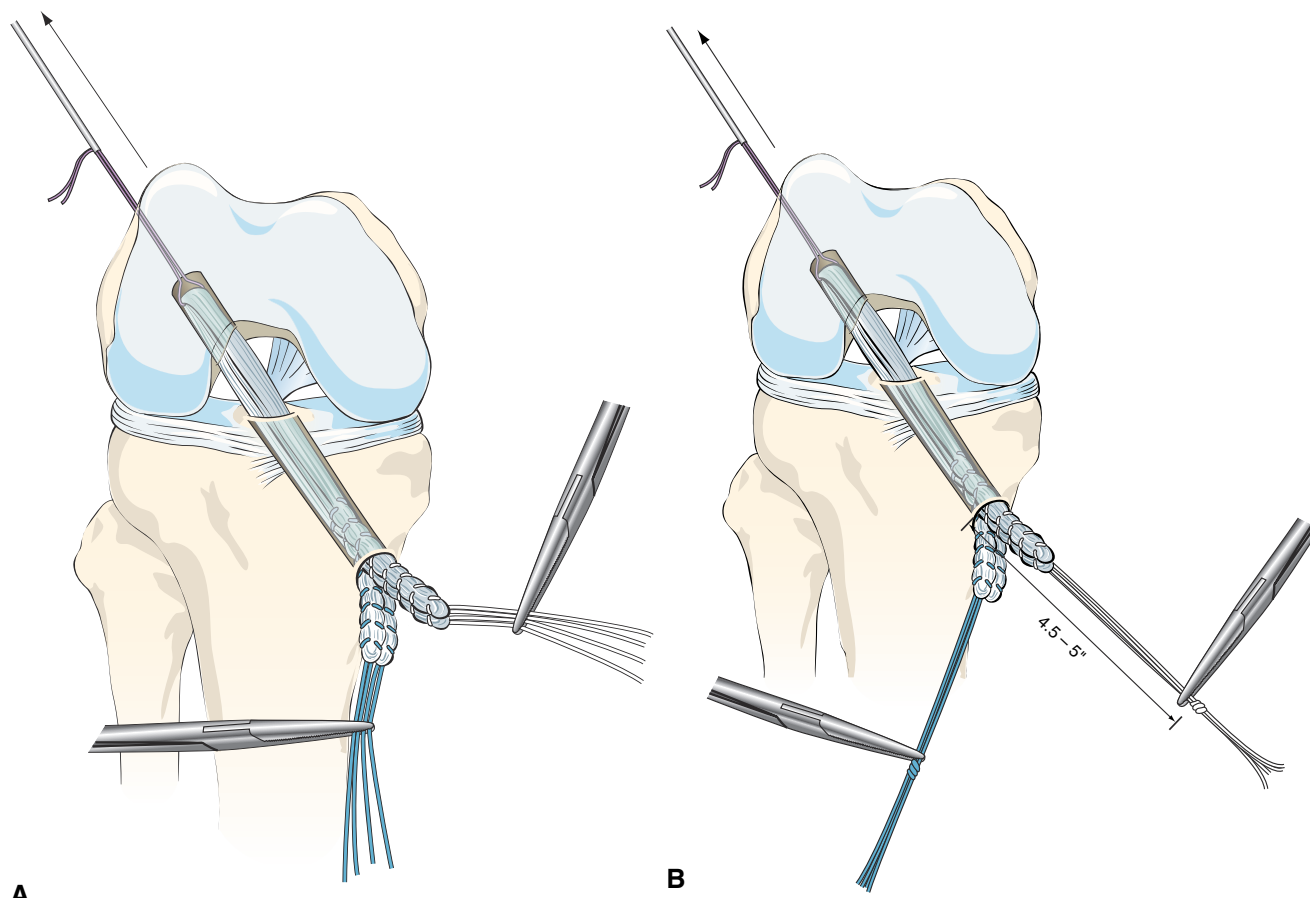
At present the optimal graft tension and knee flexion angle at the time of tibial fixation are unknown. The usual excursion pattern detected with our bone tunnel placements results in the DGST graft pulling into the tibial tunnel a few millimeters during the last 20 degrees of terminal extension. When minimal graft excursion is detected, we fix the graft with the knee at 20 degrees of flexion because it is easier to do so at this position. When a larger excursion is detected, we fix the tibial side near full extension. Because of the high fixation strength and stiffness and the resistance to slippage of the IntraFix and Bio-IntraFix, we caution against applying excessive tension (greater than 80N) to the graft and against fixing the knee at a flexion angle greater than 20 degrees. High graft tension results in the graft construct being under tension through a greater range of motion, subjects the graft to higher abrasion forces at the femoral tunnel edge (killer angle) during knee motion, and can overconstrain or "capture" the knee.

### Device Insertion

s0090

Concentric device placement within the tibial tunnel is critical to the success of the technique. To achieve this, the central axis of the tibial tunnel is identified by passing a stout guide-wire or a Trailblazer (Smith & Nephew Endoscopy, Andover, MA) through the center of the tie tensioner and down the center of the four graft strands into the knee joint (Fig. 47-5). Once the central axis of the tibial tunnel is identified, the tie tensioner should be held in this orientation during all the subsequent steps to avoid divergent placement of the IntraFix sheath and screw. The surgeon can improve his or her ability to maintain this orientation by placing several fingers or the entire side of the hand holding the tensioner on the tibia during the next steps. Next, the four-quadrant dilator is inserted down the center of the four graft strands and oriented so that each graft strand sits in its own channel (Fig. 47-6). While maintaining the desired tension on the graft, the four-quadrant dilator is tapped into the tibial tunnel for a distance of 35 mm. This step compresses and separates the four tendon strands, and, in the case of smaller tunnels (7 to 8 mm), notches the bone tunnel wall to accept the sheath. It is important to keep the dilator oriented along the axis of the tibial tunnel as it is impacted because the dilator

p0170



**FIG. 47-4 A,** The use of differently colored sutures on the gracilis and semitendinosus tendons helps with identification during graft tensioning and tibial fixation. **B,** The sutures are marked between 4.5 and 5 inches from the edge of the tibial tunnel. A hemostat can be used to hold this location during knot tying. The two gracilis suture limbs and the two semitendinosus suture limbs are tied together, creating a suture loop.

has a tendency to diverge, as do most tunnel dilators. Because the sheath for the IntraFix and Bio-IntraFix is 9 mm in diameter, the four-quadrant dilator also enlarges the tibial tunnel in the case of smaller tunnels, providing easier insertion of the IntraFix sheath and tapered screw. There are now two sheaths for the Bio-IntraFix and a smaller and larger dilator appropriate to each. The smaller sheath is used for 7- and 8-mm tunnels and the larger for 9- and 10-mm tunnels.

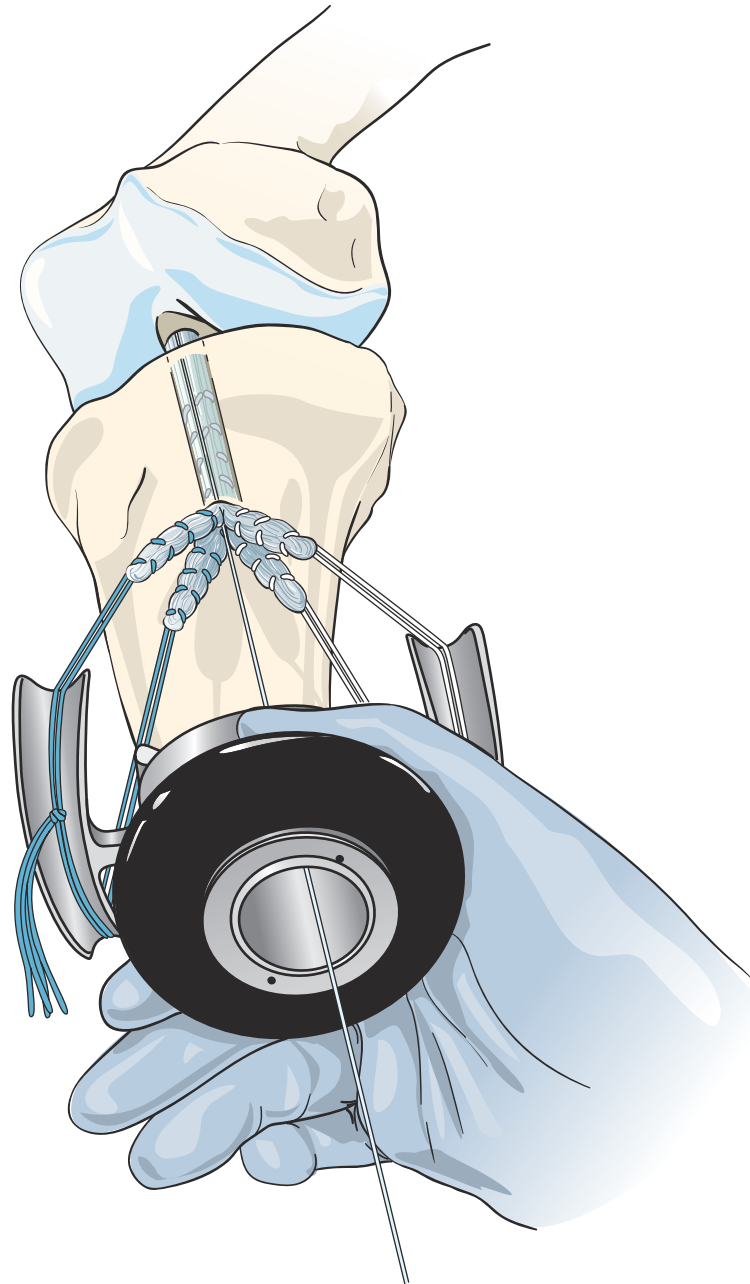
After dilating the tibial tunnel, the 30-mm Intrafix sheath is placed on the sheath inserter with the derotational tab on the sheath oriented to match the tab on the sheath inserter. The knee is positioned at the chosen flexion angle, and a final tension of 60N to 80N is applied to the DGST graft or tibialis tendon allograft using the tie tensioner.

The Intrafix sheath is inserted among the four graft strands, taking care that each graft strand is positioned into a separate channel of the IntraFix sheath. The derotational tab on the sheath is oriented at the 3- or 9-o'clock position (Fig. 47-7). Orienting the derotational tab at these positions allows the IntraFix sheath to be inserted more deeply into

the tibia and prevents prominence of the device. The inserter is tapped into the tunnel until the derotational tab is flush with the cortex. As stated earlier, clearing the soft tissue from the bone tunnel opening will allow for better assessment of the depth of insertion and trimming of any protruding tendon or sheath after the screw has been inserted. The sheath inserter is removed, and the 0.042-inch guidewire for the IntraFix tapered screw is inserted through the center of the sheath until a loss of resistance is felt as the tip of the guidewire enters the knee joint.

For the plastic IntraFix, a tapered screw size 1 mm larger than the tibial tunnel diameter is used. For example, an 8-mm tapered screw is used for a 7-mm tibial tunnel. Given the typical size of DGST grafts, the 7- to 9-mm tapered screw is most commonly used. The IntraFix screw is inserted into the plastic sheath until its inferior aspect is flush with or buried just below the tibial cortex (Fig. 47-8). Because the best bone quality is at or next to the tibial cortex, overly deep insertion of the screw may decrease fixation strength.<sup>18</sup> The tension on the graft

p0200



f0050 **FIG. 47-5** The resulting suture loop from the gracilis and semitendinosus tendons is looped over the arms of the tie tensioner. The tie tensioner will equally tension and separate each strand of the graft. The central axis of the tibial tunnel is identified by passing a 1.1-mm guidewire through the center of the tie tensioner and down the center of the four graft strands into the knee joint.

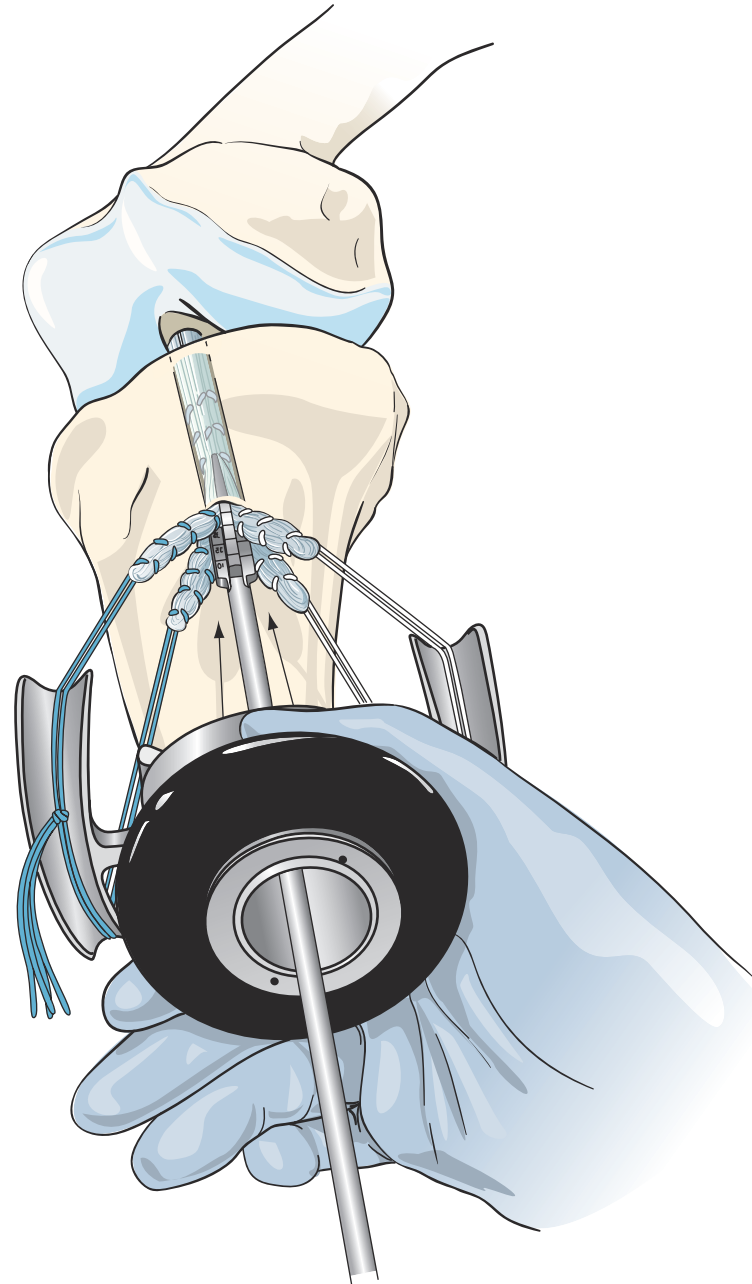
strands from the tie tensioner should prevent the sheath from rotating during screw insertion in hard bone, but some rotation of the outer sheath is acceptable because the sheath within the tunnel does not move in concert. Protruding or prominent areas of the polyethylene sheath are trimmed flush with the tibial cortex using a 15 blade and a small bone rongeur.

**Au7**

p0210

The technique for insertion of the Bio-IntraFix device is identical, but the sizing scheme differs from that just

described (Table 47-2). Because the PLLA/TCP sheath is noncompressible and because the insertion torque is higher than with the plastic version, the tunnel should be drilled or dilated 1.0 mm larger than the graft diameter. The Bio-IntraFix sheath adds more than 1 mm to the diameter of the Bio-IntraFix screw, so in effect the fixation device in total is oversized to the tunnel diameter, which is the usual practice with interference screws and with the plastic IntraFix.



f0060 **FIG. 47-6** Insertion of the four-quadrant trial dilator. The dilator is oriented so that each graft strand is positioned in its own channel. The dilator will separate and compress the tendons while preparing a bony channel for the IntraFix sheath.

p0220

The stability and range of motion of the knee are checked. It is important to verify that the patient has full range of motion before leaving the operating room. The arthroscope is inserted into the knee, and graft tension and impingement are assessed. Our usual graft placement and tensioning technique results in the four strands of the DGST being maximally tight between 0 and 20 degrees, with the graft tension decreasing slightly as the knee is flexed to 90 degrees.

## Troubleshooting

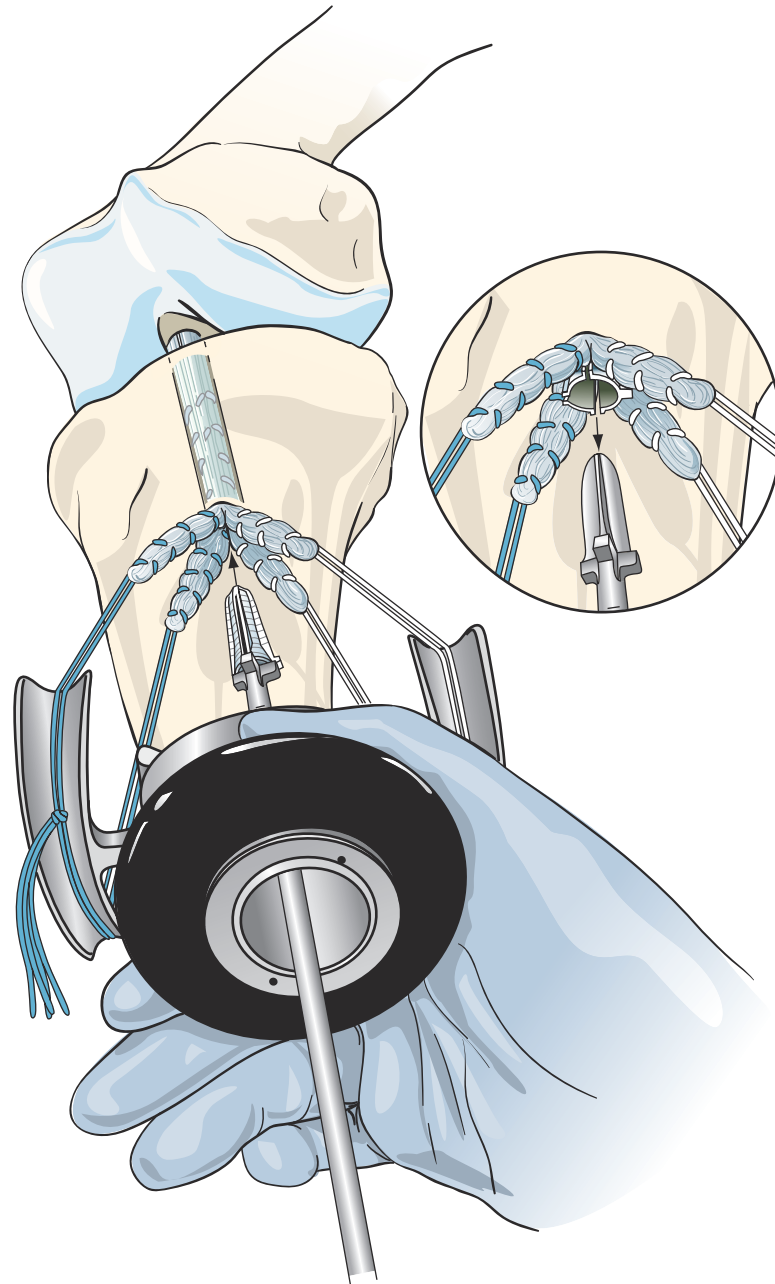
### Sheath Overinsertion

As with any fixation device, potential errors can be made during the use of the IntraFix device. Overinsertion of the sheath is one such error. This problem typically occurs when a sheath smaller than the tunnel size is driven into the tunnel and the sheath's advancement is not controlled. When this happens, the opening to the sheath cannot be seen

s0100

s0110

p0230

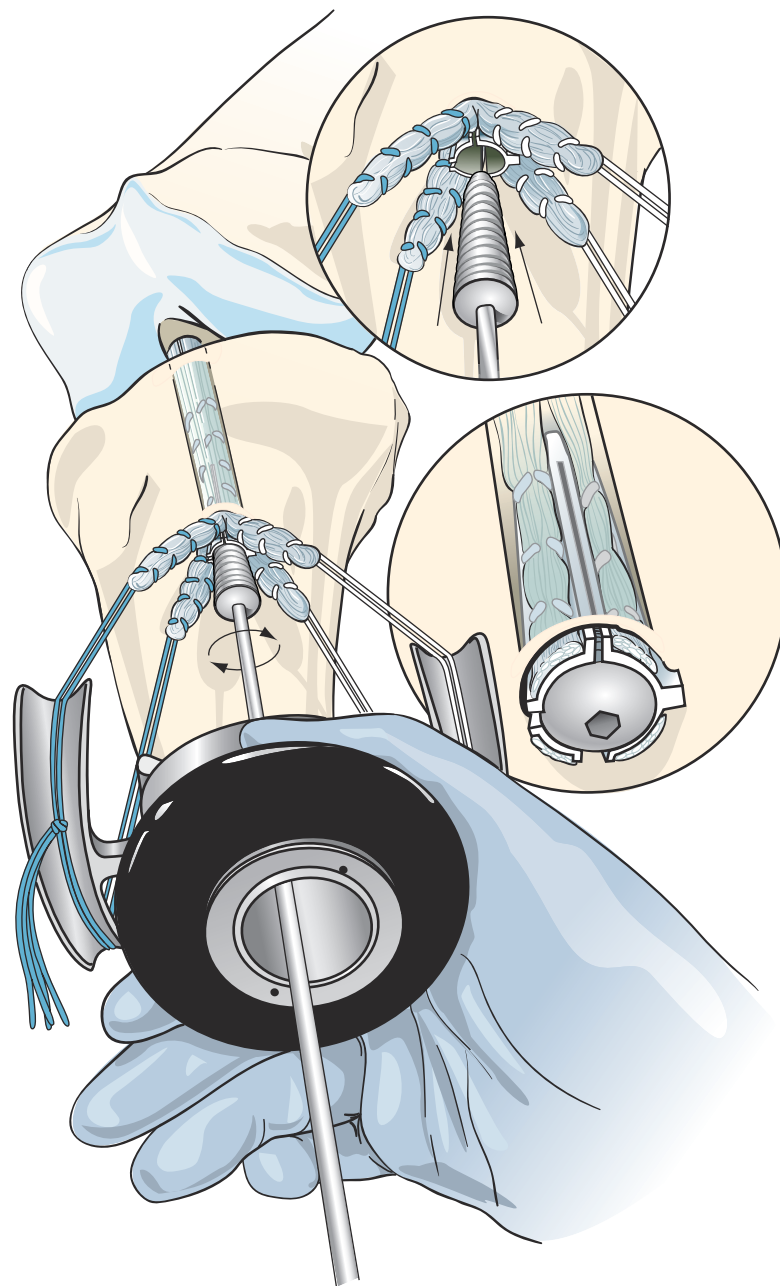


f0070 **FIG. 47-7** Insertion of the 30-mm IntraFix sheath. The knee is positioned at the chosen flexion angle, and the selected tension is applied to the graft using the tie tensioner. The 30-mm IntraFix sheath is inserted down the center of the doubled gracilis and semitendinosus graft, parallel to the axis of the tibial tunnel. The derotational tab on the sheath is positioned at the 3- or 9-o'clock position, with each tendon graft strand positioned in its own channel.

and central placement of the screw cannot be assured. If the sheath is far into the tunnel, screw insertion should be abandoned until the sheath is pulled back into position or removed and another sheath is inserted. Because the ridges on the sheath are slanted to resist slippage of the graft proximally, attempts to grasp the sheath and pull it out of the tibial tunnel are often unsuccessful. Cutting the sheath or

blindly grabbing it with an instrument such as a pituitary rongeur can damage the graft strands and the sutures holding them, risking rupture during tensioning. A better method involves pushing the sheath further up the tunnel, together with pulling the graft proximally with a probe inside the joint until the sheath can be seen entering the knee joint. At this point, the sheath can be grasped and





f0080 **FIG. 47-8** Insertion of the IntraFix tapered screw. The selected graft tension is maintained on the graft strands using the tie tensioner, with the knee at the chosen flexion, and the IntraFix tapered screw is inserted along the guidewire into the IntraFix sheath. The IntraFix tapered screw is advanced until the superior edge of the screw is just below the anterior tibial cortex.

removed through one of the portals, usually in pieces. The graft is then retensioned using the tensioner, and the standard steps noted above are repeated.

#### s0120 **Screw Breakage**

p0240 With the introduction of the PLLA/TCP Bio-IntraFix, screw breakage has sometimes occurred during insertion. This problem is partly due to the friction between the screw and sheath, which was never a concern with the plastic

IntraFix, and in part because the tunnel may not have been enlarged above the diameter of the graft as recommended. (At the time of this writing, a newer, more robust screw and a sheath with improved properties have been produced, which will make breakage much less likely.) A third factor that can lead to screw breakage is failure to insert the screw along the central axis of the sheath and tunnel. A fourth cause is failure to seat the screwdriver fully within the screw. Au8

t0020 **TABLE 47-2** Sizing Scheme for IntraFix

Au13	Graft Diameter	Drill Tunnel	Screw Size
	7 mm	7 mm	6–8 mm
	8 mm	8 mm	7–9 mm
	9 mm	9 mm	8–10 mm
	10 mm	10 mm	8–10 mm

p0250 When screw breakage happens, it is most often early during insertion, and it is nearly impossible to withdraw the screw tip with the driver due to a lack of purchase. Furthermore, the screw seems to bind within the sheath. The surgeon has two basic options at this point. The first approach is to revise the entire construct. In this case we use an “easy-out” device, such as those marketed to remove stripped cannulated interference screws, and core the screw out from within the sheath. Sometimes a new smaller screw can be inserted in its place and into the same sheath, but more commonly the sheath needs to be replaced. If the smallest of the screws (6 to 8 mm) was used initially, another screw of the same size is likely to suffer the same fate. A better strategy is to remove the sheath with a grasper and then to insert the larger 9-mm dilator more deeply into the tunnel among the graft strands, enlarging the tunnel further. After a new sheath is placed, a new screw should be carefully inserted along the axis of the tunnel. Blood, fatty tissue, or saline can be used to reduce insertion torque and should be tried during screw insertion in such instances, especially if the patient’s bone is hard and if additional tunnel dilation efforts did not seem to enlarge the diameter very much. The second technique, which is less commonly used, is to take the sutures from the tendon ends and tie them down onto a staple or screw distal to the tunnel. This approach can only be recommended if there is a significant length (greater than 50%) of screw within the sheath so that the sheath construct will not collapse when the sutures are tied below and migration of the device will not occur.

### s0130 p0260 Failure to Advance

A related screw insertion problem is failure of the screw to advance until it is fully seated. This has primarily been a problem with the Bio-IntraFix. The main cause is a tunnel diameter too small to accommodate the size of the IntraFix or Bio-IntraFix that was chosen. This situation, although quite rare, may be more challenging than screw breakage. The fact that the screw failed to advance almost certainly indicates that the screw has gained good purchase, at least in the distal portion of the tunnel. Therefore if the screw is no more prominent than an external fixation device such as a screw-washer, then it can probably be left in place,

although it may require later removal after the graft has healed. If a much longer portion protrudes and it cannot be withdrawn with the screwdriver, then the protruding portion must be removed with a saw; the inserted portion and sheath removed; and a new, more properly sized device inserted.

### Low Bone Density

The fixation strength of any intratunnel fixation device is dependent on the local bone mineral density. If, during the insertion of the tapered screw, the surgeon subjectively feels that there was low insertion torque, or if the patient has soft bone as assessed during drilling and dilation of the tunnel, then we recommend that supplemental tibial fixation be used.<sup>15</sup> Depending on the graft length, the tendons can be stapled below the tibial tunnel opening using one or two small barbed staples (Smith & Nephew Orthopaedics, Memphis, TN). Another method of backup is to tie the sutures around a small nonbarbed staple, a screw and washer, or a tibial fixation post (Smith & Nephew Endoscopy).

### Too Short a Graft

Finally, the surgeon may be faced by a graft that is not long enough and with ends that are recessed in the tunnel. If the graft is recessed to the degree that identification of the individual strands is not possible, then concentric placement of the sheath becomes much more difficult. One could try to separate the strands blindly, but then insertion of the dilator runs the risk of rupturing the sutures, with loss of ability to tension. In this case, therefore, it is probably best to tie the sutures onto a fixation post or use an interference screw as the sole means of fixation, or to use a hybrid of the two methods.

### Closure and Postoperative Dressings

A Hemovac drain can be inserted under the sartorius fascia and into the hamstring harvest site to prevent postoperative hematoma formation and decrease subcutaneous skin ecchymosis along the medial side of the knee.<sup>28</sup> This is particularly useful when excessive bleeding is encountered during the hamstring tendon harvest. The sartorius fascia that was preserved during the hamstring tendon graft harvest is closed over the tibial hardware and repaired back to the tibia with a #0 absorbable suture. The subcutaneous tissue is closed in layers with fine absorbable sutures. A running #3-0 Prolene (Ethicon, Sommerville, NJ) subcuticular pull-out suture or #4-0 Monocryl produces a very cosmetic closure. A light dressing is applied over the wound, followed by a thigh-length TED antiembolism stocking (Cryocuff, Air-cast, Summit, NJ) and knee immobilizer.

## POSTOPERATIVE MANAGEMENT

s0170

p0300

The procedure is routinely performed as an outpatient procedure. If a Hemovac drain is used, the drain is removed when the patient is discharged from the day surgery unit. We allow unrestricted motion and weight bearing as tolerated. Early flexion performed as heel slides is encouraged because it prevents scarring of the extensor mechanism.

p0310

The weight-bearing schedule is modified if a meniscus repair, microfracture, or other associated ligamentous surgery has been performed. The patient is weaned from the knee immobilizer when quadriceps control is regained. Crutches are continued until the patient has regained a normal gait pattern. Riding a stationary bike can be started when the patient has at least 100 degrees of flexion. Closed chain strengthening exercises using a leg press machine, elliptical cross-trainer, StairMaster, and step-ups are started around 4 to 6 weeks after surgery. During the first 3 months after surgery, the hamstring donor site must be protected by avoiding sudden hamstring stretching with the hip and knee in extension. This position is commonly encountered during activities of daily living such as bending down to tie shoes or put on socks or reaching down to pick an object off the floor. We also recommend that isolated hamstring resistive exercises performed in the prone position be avoided for the first 2 to 3 months. Isolated hamstring strengthening exercises using a seated leg curl machine can usually be started after 6 to 8 weeks if tenderness is not present or is minimal at the hamstring donor site. We allow jogging and running at 3 to 4 months, side-to-side cutting at 4 to 5 months, a return to noncontact sports at 5 to 6 months, and a return to unrestricted sports at 6 to 7 months. In revision cases, we recommend that a return to unrestricted sports be delayed until 9 months.

## RESULTS

s0180

p0320

We report the preliminary results of the first 84 patients operated on by Dr. Joseph H. Sklar using a DGST graft with Endobutton-CL femoral fixation and tibial fixation with the IntraFix tibial fastener. The mean age of the patients was 30 years (range 16–54 years). Of the patients, 46 were male and 38 were female. The mean diameter of the DGST graft for all patients was 8.3 mm (range 7–9.5 mm) and 7.9 mm for females. The mean KT-1000 side-to-side difference for all patients at the 12-month follow-up was 1.8 mm, with 83% having a side-to-side difference of 0 to 3 mm; 13%, 3 to 5 mm; and 3%, greater than 5 mm. At the 24-month follow-up, the mean KT-1000 side-to-side difference was 1.78 mm, with 85% having a side-to-side difference of 0 to

3 mm; 11%, 3 to 5 mm; and 4%, greater than 5 mm. For female patients, the mean KT-1000 side-to-side difference was 2.3 mm, with 80% having a side-to-side difference of 0 to 3 mm; 20%, 3 to 5 mm; and no patient had a difference greater than 5 mm. Supplemental tibial fixation was used in 17% of the male patients and 42% of the female patients. There were no postoperative infections in the group, and no patient had a loss of extension. Flexion averaged 138 degrees at 24 months. Two patients required an early manipulation under anesthesia to regain flexion. No patient has required a second operation to remove prominent hardware.

## CONCLUSION

In summary, the IntraFix and Bio-IntraFix devices provide strong rigid tibial fixation that is superior to the fixation properties of interference screws and most external fixation methods. The device grips each of the graft strands in its own separate compartment and increases the amount of graft in direct contact with the cancellous bone of tunnel, potentially increasing the amount of bone-tendon healing. Successful use of the device depends on proper tunnel preparation and sizing and the concentric insertion of the device parallel to the axis of the tunnel. In cases in which doubt exists about the hardness of the bone, the IntraFix and Bio-IntraFix can be used in combination with cortical backup fixation.

## References

1. Aglietti P, Giron F, Buzzi R, et al. Anterior cruciate ligament reconstruction: bone-patellar tendon-bone compared with double semitendinosus and gracilis tendon grafts. *J Bone Joint Surg* 2004;86A:2143–2162. Au14
2. Brand JC, Weiler A, Caborn DN, et al. Graft fixation in cruciate ligament reconstruction. *Am J Sports Med* 2000;28:761–774.
3. Brown CH, Sklar JH. Endoscopic anterior cruciate ligament reconstruction using quadrupled hamstring tendons and Endobutton femoral fixation. *Tech Orthop* 1998;13:281–298.
4. Brown CH, Wilson DR, Hecker AT, et al. Graft-bone motion and tensile properties of hamstring and patellar tendon anterior cruciate ligament femoral graft fixation under cyclic loading. *Arthroscopy* 2004;20:922–935.
5. Cooper DE, Deng XH, Burstein AL, et al. The strength of central third patellar tendon graft. A biomechanical study. *Am J Sports Med* 1993;21:818–824.
6. Corry IS, Webb JM, Clingeleffer AJ, et al. Arthroscopic reconstruction of the anterior cruciate ligament. A comparison of patellar tendon autograft and four-strand hamstring tendon autograft. *Am J Sports Med* 1999;27:444–454.
7. Howell SM, Clark JA, Farley TC. A rationale for predicting anterior cruciate graft impingement by the intercondylar roof: an MRI study. *Am J Sports Med* 1991;19:276–281.
8. Howell SM. Principles for placing the tibial tunnel and avoiding roof impingement during reconstruction of a torn anterior cruciate ligament. *Knee Surg Sports Traumatol Arthrosc* 1998;6:S49–S55.

## Anterior Cruciate Ligament Reconstruction

9. Howell SM, Taylor MA. Failure of reconstruction of the anterior cruciate ligament due to impingement by the intercondylar roof. *J Bone Joint Surg* 1993;75A:1044-1055.
10. Kartus J, Magnusson L, Stener S, et al. Complications following arthroscopic anterior cruciate ligament reconstruction. A 2-5 year follow-up of 604 patients with special emphasis on anterior knee pain. *Knee Surg Sports Traumatol Arthrosc* 1999;7:2-8.
- Au12** 11. Ahmad CS, Gardner TR, Groh M, et al. Mechanical properties of soft tissue femoral fixation devices for anterior cruciate ligament reconstruction. *Am J Sports Med* 2004;32:635-640.
12. Brown CH, Sklar JH. Endoscopic anterior cruciate ligament reconstruction using doubled gracilis and semitendinosus tendons and Endobutton femoral fixation. *Oper Tech Sports Med* 1999;7:201-213.
13. Breitfuss H, Frohlich R, Povacz P, et al. The tendon defect after anterior cruciate ligament reconstruction using the mid third patellar tendon—a problem for the patellofemoral joint? *Knee Surg Sports Traumatol Arthrosc* 1996;3:195-198.
14. Brand JC, Pienkowski D, Steenlage E, et al. Interference screw fixation strength of a quadrupled hamstring tendon graft is directly related to bone mineral density and insertion torque. *Am J Sports Med* 2000;28:705-710.
15. Goble EM, Downey DJ, Wilcox TR. Positioning of the tibial tunnel for anterior cruciate ligament reconstruction. *Arthroscopy* 1995;11:688-695.
16. Levy M, Prudhomme J. Anatomic variations of the pes anserinus: a cadaver study. *Orthopedics* 1993;16:601-606.
17. Jansson KA, Harilainen A, Sandelin J, et al. Bone tunnel enlargement with anterior cruciate ligament reconstruction with hamstring autograft and Endobutton fixation technique. *Knee Surg Sports Traumatol Arthrosc* 1999;7:290-295.
18. Ferrari JD, Ferrari DA. The semitendinosus: anatomic considerations in tendon harvesting. *Orthop Rev* 1991;20:1085-1088.
19. Howell SM. Roof impingement of ACL grafts: diagnosis, cause, prevention, and late surgical correction. In Feagin JA (ed). *The crucial ligaments*. New York, 1994, Churchill Livingstone, pp 637-648.
20. Kousa P, Jarvinen TLN, Vihavainen M, et al. The fixation strength of six hamstring tendon graft fixation devices in anterior cruciate ligament reconstruction. Part II: tibial site. *Am J Sports Med* 2003;31:182-188.
21. Eriksson K, Anderberg P, Hamberg P, et al. A comparison of quadrupled semitendinosus and patellar tendon grafts in reconstruction of the anterior cruciate ligament. *J Bone Joint Surg* 2001;83B:348-354.
22. Greis PE, Burks RT, Bachus K, et al. The influence of tendon length and fit on the strength of a tendon-bone tunnel complex: a biomechanical and histologic study in the dog. *Am J Sports Med* 2001;29:493-497.
23. Hamner DL, Brown CH, Steiner ME, et al. Hamstring tendon grafts for reconstruction of the anterior cruciate ligament: biomechanical evaluation of the use of multiple strands and tensioning techniques. *J Bone Joint Surg* 1999;81A:549-557.
24. Harvery AR, Thomas NP, Amis AA. The effect of screw length and position on fixation of four-stranded hamstring grafts for anterior cruciate ligament reconstruction. *Knee* 2002;10:97-102.
25. Loh JC, Fukuda Y, Tsuda E, et al. Knee stability and graft function following anterior cruciate ligament reconstruction: comparison between 11 o'clock and 10 o'clock femoral tunnel positions. *Arthroscopy* 2003;19:297-304.
26. Jackson DW, Gasser SI. Tibial tunnel placement in ACL reconstruction. *Arthroscopy* 1994;10:124-131.
27. Simmons R, Howell SM, Hull ML. Effect of the angle of the femoral and tibial tunnels in the coronal plane and incremental excision of the posterior cruciate ligament on tension of an anterior cruciate ligament graft: an in vitro study. *J Bone Joint Surg* 2003;85A:1018-1029.
28. Howell SM, Clark JA. Tibial tunnel placement in anterior cruciate ligament reconstructions and graft impingement. *Clin Orthop* 1992;283:187-195.

## Suggested Readings

- Brown CH, Sklar JH, Darwich N. Endoscopic anterior cruciate ligament reconstruction using autogenous doubled gracilis and semitendinosus tendons. *Tech Knee Surgery* 2004;3:215-237.
- Butler DL. Evaluation of fixation methods in cruciate ligament surgery. *AAOS Instruct Course Lect* 1987;36:173-178.
- Ejerhad L, Kartus J, Sernert N, et al. Patellar tendon or semitendinosus tendon autografts for anterior cruciate ligament reconstruction? A prospective randomized study with two-year follow-up. *Am J Sports Med* 2003;31:19-25.
- Hill PF, Russell VJ, Salmon LJ, et al. The influence of supplementary tibial fixation on anterior laxity measurements after anterior cruciate ligament reconstruction with hamstring tendons in female patients. *Am J Sports Med* 2005;33:94-101.
- Howell SM, Gittens ME, Gottlieb JE, et al. The relationship between the angle of the tibial tunnel in the coronal plane and loss of flexion and anterior laxity after anterior cruciate ligament reconstruction. *Am J Sports Med* 2001;29:567-574.
- Jansson KA, Linko E, Sandelin J, et al. A prospective randomized study of patellar versus hamstring tendon autografts for anterior cruciate ligament reconstruction. *Am J Sports Med* 2003;31:12-18.
- Karahan M, Erol B, Bekiroglu N, Uyan D. Effect of drain placed in the donor site in the early postoperative period after arthroscopically assisted cruciate ligament reconstruction with quadrupled hamstring tendons. *Am J Sports Med Preview* 2005;33:900-906.
- Kartus J, Movin T, Karlsson J. Donor-site morbidity and anterior knee problems after anterior cruciate ligament reconstruction using autografts. *Arthroscopy* 2001;17:971-980.
- Laxdal G, Kartus J, Hansson L, et al. A prospective randomized comparison of bone-patellar tendon-bone and hamstring grafts for anterior cruciate ligament reconstruction. *Arthroscopy* 2005;21:34-42.
- Levy M. Surgical technique for harvesting the gracilis and semitendinosus tendons. *Contemp Orthop* 1993;26:369-372.
- Magen HE, Howell SM, Hull ML. Structural properties of six tibial fixation methods for anterior cruciate ligament soft tissue grafts. *Am J Sports Med* 1999;27:35-43.
- Muneta T, Yamamoto H, Ishibashi T, et al. The effects of tibial tunnel placement and roofplasty on reconstructed anterior cruciate ligament knees. *Arthroscopy* 1995;11:57-62.
- Pagnani MJ, Warner JJ, O'Brien SJ, et al. Anatomic considerations in harvesting the semitendinosus and gracilis tendons and a technique of harvest. *Am J Sports Med* 1993;21:565-571.
- Pinczewski LA, Deehan DJ, Salmon LJ, et al. Five-year comparison of patellar tendon versus four-strand hamstring tendon autograft for arthroscopic reconstruction of the anterior cruciate ligament. *Am J Sports Med* 2002;30:523-535.
- Romano VM, Graf BK, Keene JS, et al. Anterior cruciate ligament reconstruction: the effect of tibial tunnel placement on range of motion. *Am J Sports Med* 1993;21:415-418.
- Soloman CG, Pagnani MJ. Hamstring tendon harvesting. Reviewing anatomic relationships and avoiding pitfalls. *Orthop Clin North Am* 2003;34:1-8.
- Steiner ME, Hecker AT, Brown CH, et al. Anterior cruciate ligament graft fixation: comparison of hamstring and patellar tendon grafts. *Am J Sports Med* 1994;22:240-242.
- Warren LF, Marshal JL. The supporting structures and layers on the medial side of the knee. *J Bone Joint Surg* 1979;61A:56-62.



## 10047

### Hamstring Anterior Cruciate Ligament Reconstruction with IntraFix Tibial Fastener

Woo SL-Y, Hollis JM, Adams DJ, et al. Tensile properties of the human femur-anterior cruciate ligament-tibia complex. The effect of specimen age and orientation. *Am J Sports Med* 1991;19:217-225.

Yamamoto Y, Hsu W-H, Woo SL-Y, et al. Knee stability and graft function after anterior cruciate ligament reconstruction. A comparison of a

lateral and an anatomical femoral tunnel placement. *Am J Sports Med* 2004;32:1825-1832.

Yasuda K, Onkoshi Y, Tanabe Y. Graft site morbidity with autogenous semitendinosus and gracilis tendons. *Am J Sports Med* 1994;23:705.

## Author Query Form

**Book: The Anterior Cruciate Ligament: Reconstruction and Basic Science**  
**Chapter No: 10047**

Query Refs.	Details Required	Author's response
AU1	Original references were out of order, misnumbered, 41 was listed twice, and several references were missing or not cited. Please check all refs carefully for accuracy.	
AU2	Please define PLLA/TCP if neccessary.	
AU5	Placement of callout for Figure 47-3 OK?	
AU6	Is this heading correct, or should it be the same <del>site</del> as "Femoral Tunnel" above?	
AU7	Please clarify: "in concert" with what?	
AU8	IntraFix as meant by IF?	
AU9	Ok to make "easy-out" lower case? Is it a brand name?	
AU10	Ok as edited: "under the sartorius fascia and into the hamstring harvest site"?	
AU11	Please clarify: 8.3 mm mean for all patients but 7.9 mm for females? Does 8.3 refer to males?	
AU12	Ref 10 was one of the repeated #41s in the original ms. Please verify that this is the correct reference referred to in the text.	
AU13	Are these table column heads correct?	
AU14	The following references numbers were given in the original ms, but the references were missing from the list: 3, 7, 13, 16, 18, 24, 26, 28, 29, 35, 36, 47, 49, 52, 53, 57, 58, 62, 63, 65...please address.	